

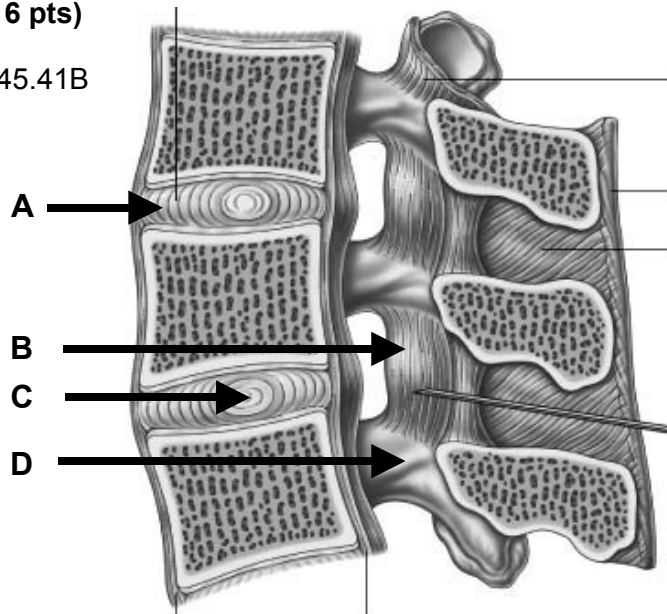
**STRUCTURAL BASIS OF MEDICAL PRACTICE
EXAMINATION 5**

October 3, 2008

PART I. Answer in the space provided. (16 pts)

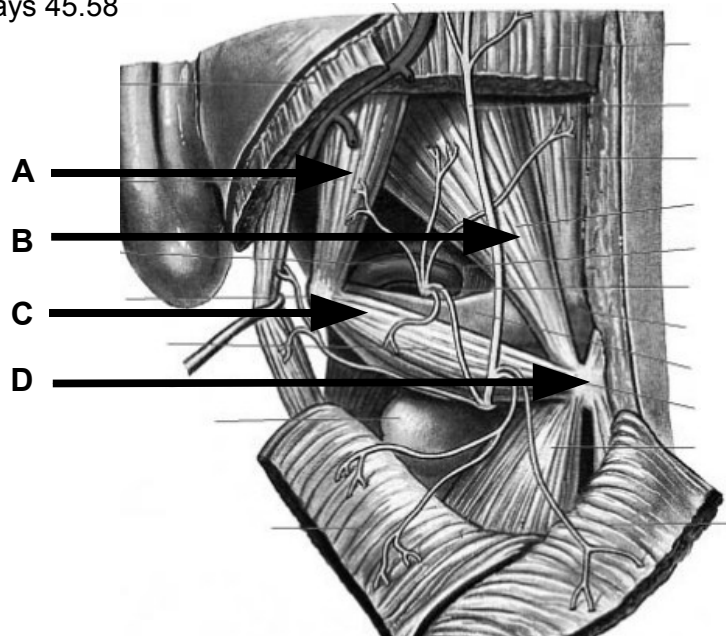
1. Identify the structures. (2 pts) Grays 45.41B

- A. Anulus fibrosus
- B. Ligamentum flavum
- C. Nucleus pulposus
- D. Lamina



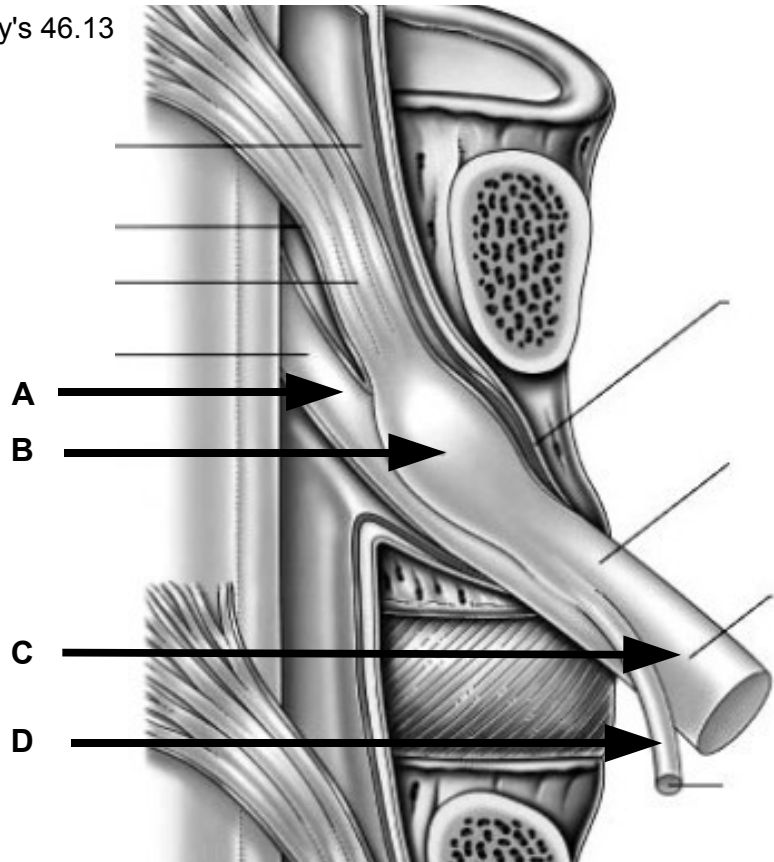
2. Identify the structures. (2 pts) Grays 45.58

- A. Obliquus capitis superior
- B. Rectus capitis posterior major
- C. Obliquus capitis inferior
- D. Spine of axis



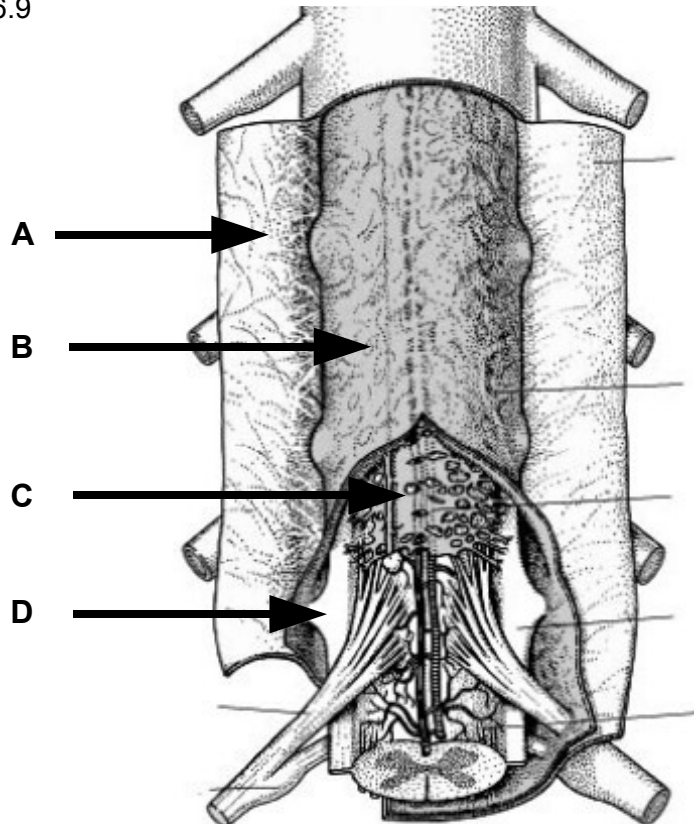
3. Identify the structure.(2 pts) Gray's 46.13

- A. Ventral root
- B. Dorsal root ganglion
- C. Ventral ramus
- D. Dorsal ramus



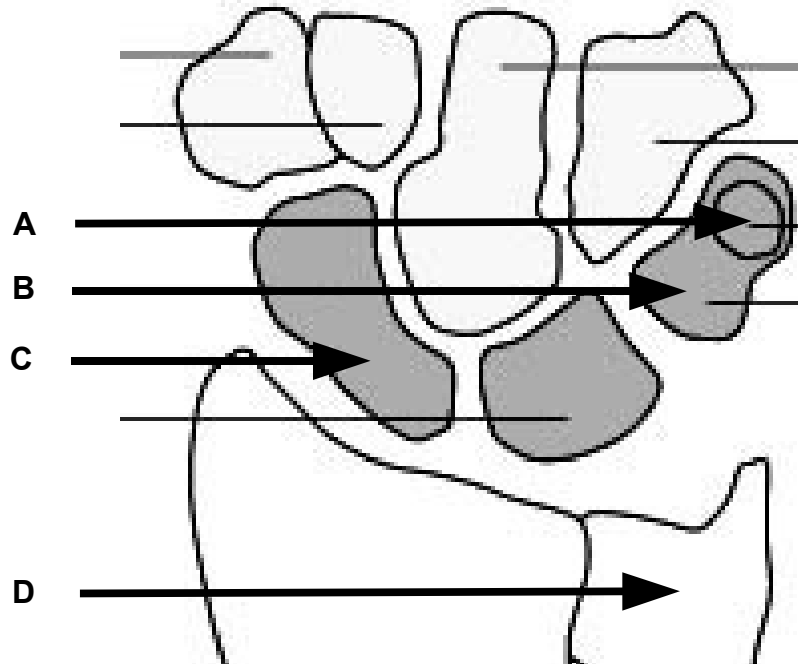
4. Identify the structure. (2 pts) Gray's 46.9

- A. Dura mater
- B. Arachnoid mater
- C. Arachnoidia, pia, SAS +
- D. Denticulate ligament



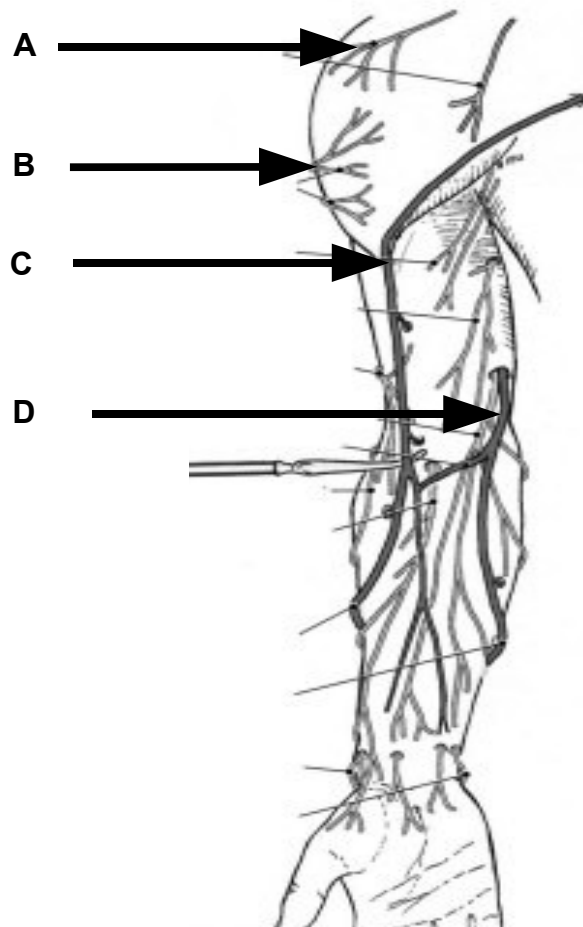
5. Identify the structure. (2 pts) Gray's 53.33

- A. Pisiform
- B. Triquetrum
- C. Scaphoid
- D. Ulna



6. Identify the structure. (2 pts) Grant's 2.03

- A. Supraclavicular nerves
- B. Superior lateral cutaneous nerve arm
- C. Cephalic vein
- D. Basilic vein



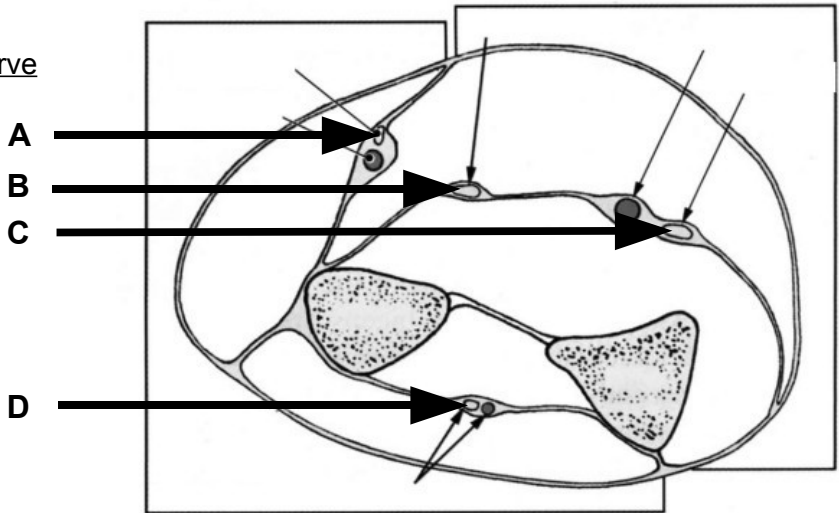
7. Identify the nerves. (2 pts) Grants 2.16

A. Superficial radial nerve

B. Median nerve

C. Ulnar nerve

D. Posterior interosseous nerve



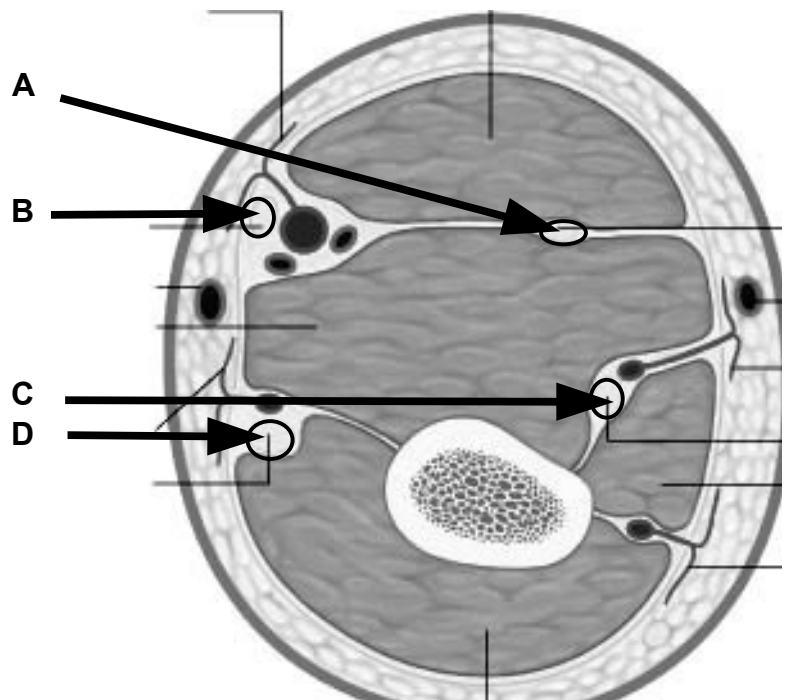
8. Identify the nerves. (2 pts) Gray's 50.2

A. Musculocutaneous nerve

B. Median nerve

C. Radial nerve

D. Ulnar nerve



Part II. Circle the correct answer. All, none, or some may apply. (16 pts)

1. With regard to the back, suboccipital region, and vertebral column:
 - a. The anterior longitudinal ligament forms, in part, the anterior boundary of the spinal canal. **False**
 - b. The spinal cord requires blood from radicular arteries for sufficient arterial supply. **True**
 - c. The serratus posterior superior raises the upper ribs and is, thus, a muscle of inspiration. **True**
 - d. The transversospinal group of muscles are innervated by the dorsal rami of spinal nerves. **True**
 - e. The obliques capitis inferior rotates the head to the opposite side. **False**
 - f. There are 7 cervical nerves and 8 cervical vertebrae. **False**
2. With regard to the axilla:
 - a. The medial wall of the axilla is largely made up of the serratus posterior superior. **False**
 - b. Ligation of the axillary artery distal to the thyrocervical trunk and proximal to the subscapular artery causes reverse (retrograde) blood flow in the circumflex scapular artery. **True**
 - c. The axillary artery is divided into 3 segments according to its relationships to the teres major. **False**
 - d. The third segment of the axillary artery gives rise to the posterior humeral circumflex artery. **True**
3. With regard to the arm:
 - a. A gap superior to the superior free edge of the interosseous membrane and inferior to the oblique cord provides passageway for the anterior interosseous artery to leave the anterior forearm to enter the posterior forearm. **False**
 - b. The brachial artery begins medial to the median nerve in the upper arm, and then crosses to the lateral side of the median nerve as it approaches the cubital fossa. **True**
 - c. The long head of the biceps brachii originates from the infraglenoid tubercle. **False**
 - d. The middle collateral artery remains in the posterior compartment of the arm and passes posterior to the lateral epicondyle. **True**
 - e. Both the coracobrachialis and the short head of the biceps flex the forearm, and both arise from the coracoid process. **False**
4. With regard to the forearm:
 - a. The pisiform bone is a site of insertion for the flexor carpi ulnaris and a site of origin for the abductor digiti mini. Thus, movement of the flexor carpi ulnaris can be observed during forceful abduction of the fifth digit. **True**

- b. The tendons of flexor digitorum profundus, at the level of the proximal phalanx, are posterior to the tendons of flexor digitorum superficialis. **True**
- c. The pronator quadratus receives the most distal motor innervation of the anterior interosseous nerve. **True**
- d. The radial two tendons of the flexor digitorum profundus are innervated by the radial nerve. **False**
- e. Entrapment of the ulnar nerve within the heads of origin of flexor carpi ulnaris may weaken flexion of the distal interphalangeal joint of the second digit. **False**
- f. The brachioradialis, innervated by the radial nerve, flexes the elbow and extends the wrist. **False**

5. With regard to the hand:

- a. The interosseous and lumbrical muscles resist hyperextension at the metacarpophalangeal joint. **True**
- b. The lumbrical muscles arise from the medial side of the flexor digitorum longus tendon. **False**
- c. Both the ulnar and radial arteries contribute to the deep arch and the superficial arch of the palm, but the main contribution to the superficial arch is by the radial artery and the main contribution to the deep arch is by the ulnar artery. **False**
- d. The dorsal carpal branch of the radial artery, dorsal carpal branch of the ulnar artery, posterior interosseous artery, and the anterior interosseous artery all contribute to the dorsal carpal rete (arch). **True**
- e. The superficial radial nerve can be palpated crossing superficial to the tendons that define the anatomical snuff box. **True**
- f. The muscles of the thenar eminence are innervated by the recurrent median nerve. **True**
- g. The dorsal and palmar interosseous muscles cross anterior to the axis of the metacarpophalangeal joint and, thus, like the lumbrical muscles, extend this joint. **False**
- h. The lateral bands of the extensor apparatus (extensor hood) extend distal to the central band and insert on the posterior surface of the distal phalanx. **True**

6. With regard to the joints:

- a. A complete rupture of the acromioclavicular joint capsule results in shoulder dislocation. **False**
- b. An articular disk that intervenes between the ulnar head and the triquetrum limits adduction. **True**
- c. The collateral ligaments of the metacarpophalangeal, proximal interphalangeal, and distal interphalangeal joints tighten on extension. **False**

Part III. Indicate your understanding (characteristics, importance, function, relationships, boundaries and/or contents) of the following. Answer in the space provided. (16 pts)

1. Intervertebral disk. (4 pts)

2. Denticulate ligament. (4 pts)

3. Ligamentum flavum. (4 pts)

4. Hook of the hamate. (4 pts)

Part IV. Indicate your understanding (characteristics, importance, function, relationships, boundaries and/or contents) of the following. Answer in the space provided. (16 pts)

1. Spiral groove. (4 pts)

2. Deep palmar arch. (4 pts)

3. Extensor apparatus (hood) of index finger. (4 pts)

4. Anatomical snuff box. (4 pts)

Part V. Answer in the space provided (including the back of the page or the additional pages for each question). (36 pts)

1. A 57 y.o. male walks into a "free clinic" where you are volunteering as a first year medical student. He is complaining that his right hand is "limp" and he doesn't have much strength below the elbow. He doesn't remember any injury to his arm but states, "I really was too drunk last night to remember, anyway," Another student is worried that he has had a stroke but YOU examine the patient and find him to have weakness of his elbow and wrist extensors - when resting the arm horizontally he cannot lift his wrist against gravity. **Review the anatomy of the brachial plexus. Include relationships within the axilla. For each terminal nerve, discuss the effects of nerve injury on muscle movements and joint position. Discuss compensation for lost or weakened movements. (12 pts)**

EXAM NUMBER _____

EXAM NUMBER _____

2. A 28 y.o female tennis player complains of tenderness on the outer bony part of the elbow. She reports morning stiffness of the elbow with persistent aching and pain when the fingers and wrist are extended. **Review the anatomy of the elbow joint. Include bones, articular surfaces, cavities, capsules, ligaments, contents, muscles, movements and limitations of movement, vasculature, innervation, relationships to surrounding structures, and lymphatic drainage. (12 pts).**

EXAM NUMBER _____

EXAM NUMBER _____

3. A 55 y.o. female comes to your office with persistent right shoulder pain. She states she had begun a weight-training program recently. After increasing her weight on the military press she noted the next morning that her shoulder was quite painful. She felt she may have slept on it wrong, but it has not been improving and she is now having difficulty raising her arm above her head. On physical exam, her "oil can" test is positive on the right side. She has difficulty abducting her right arm above her shoulder. She cannot hold her right arm up when you apply resistance during abduction. **Review the anatomy of the scapular region and shoulder joint. Include bones, articular surfaces, cavities, capsules, ligaments, contents, muscles, movements and limitations of movement, vasculature, innervation, relationships to surrounding structures, and lymphatic drainage. (12 pts)**

EXAM NUMBER _____

EXAM NUMBER _____