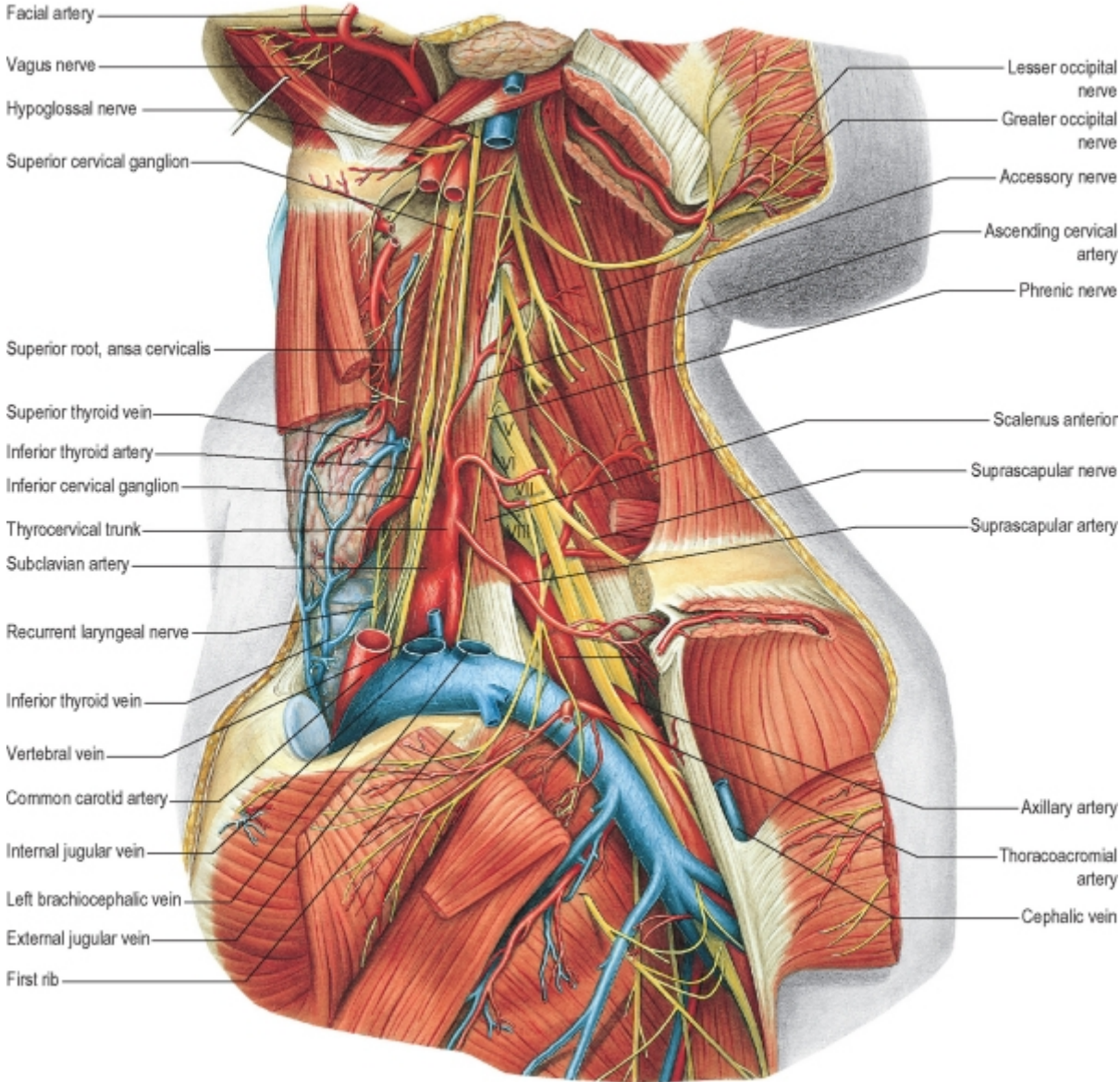


Cervical Sympathetic Trunk



Sympathetic Innervation of the Head

