

**STRUCTURAL BASIS OF MEDICAL PRACTICE**

**EXAMINATION I**

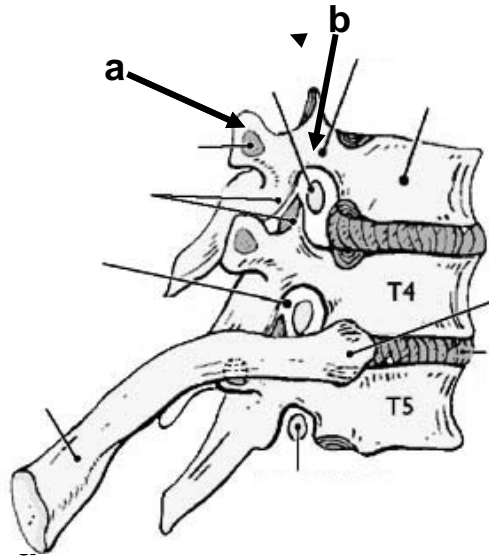
August 26, 2010

**PART I. Answer in the space provided. (6 pts)**

1. Identify the structures. (1 pt)

a. \_\_\_\_\_

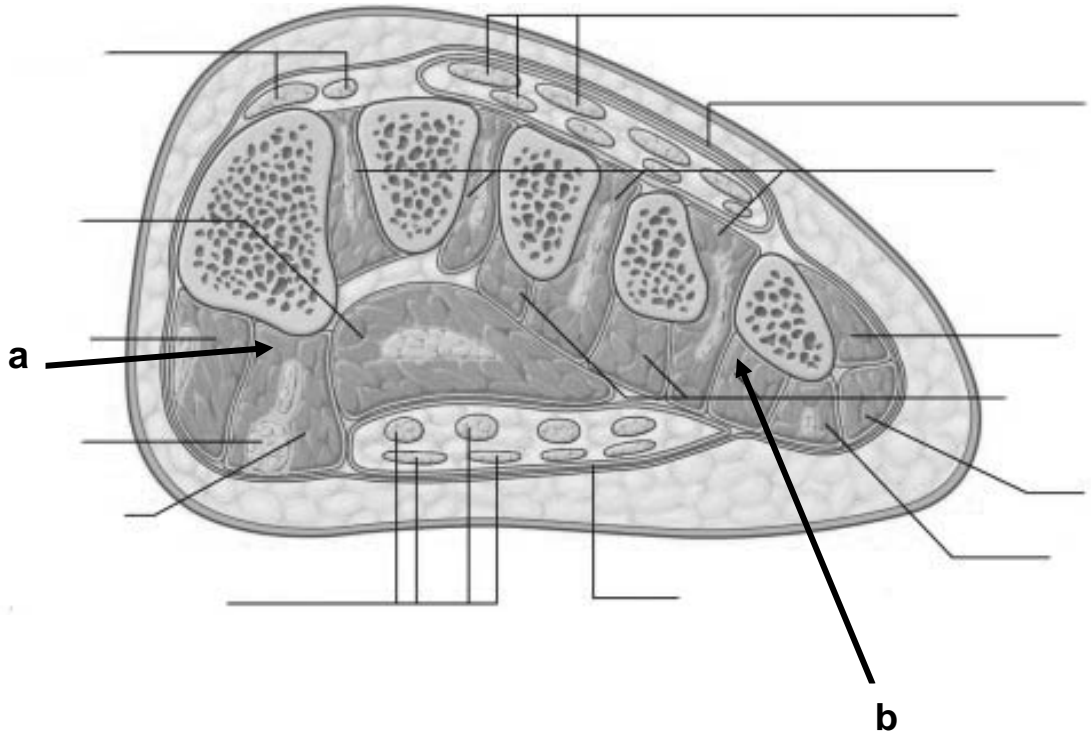
b. \_\_\_\_\_



2. Identify the structures. (1 pt)

a. \_\_\_\_\_

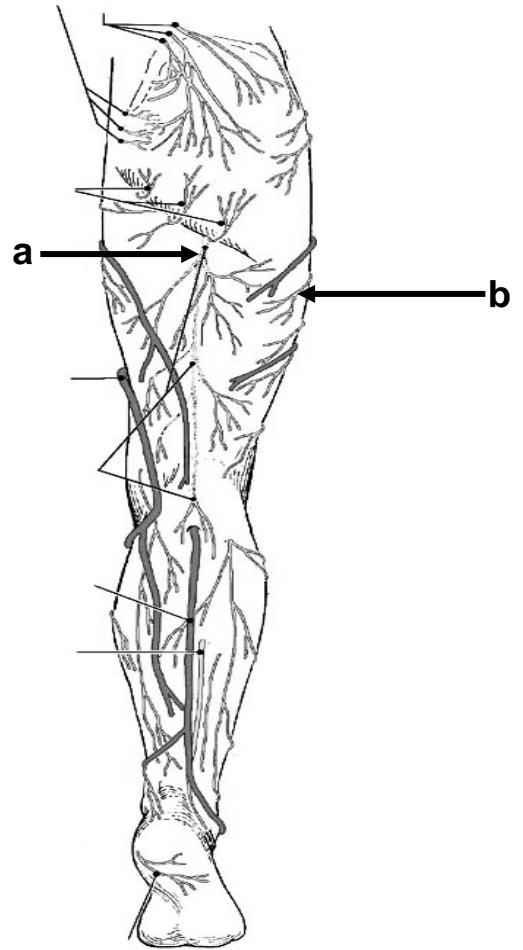
b. \_\_\_\_\_



3. Identify the nerves. (1 pt)

a. \_\_\_\_\_

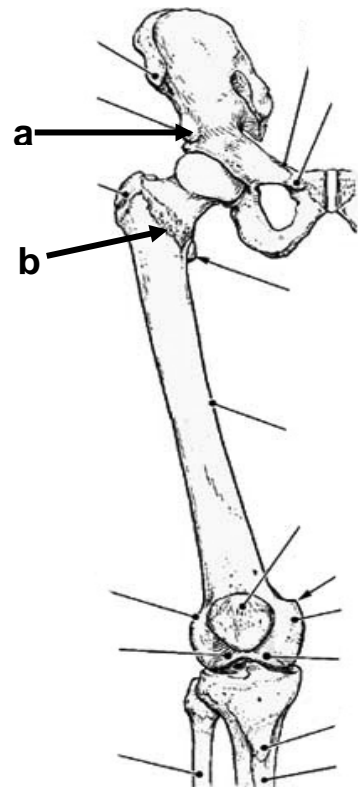
b. \_\_\_\_\_



4. Identify the structures. (1 pt)

a. \_\_\_\_\_

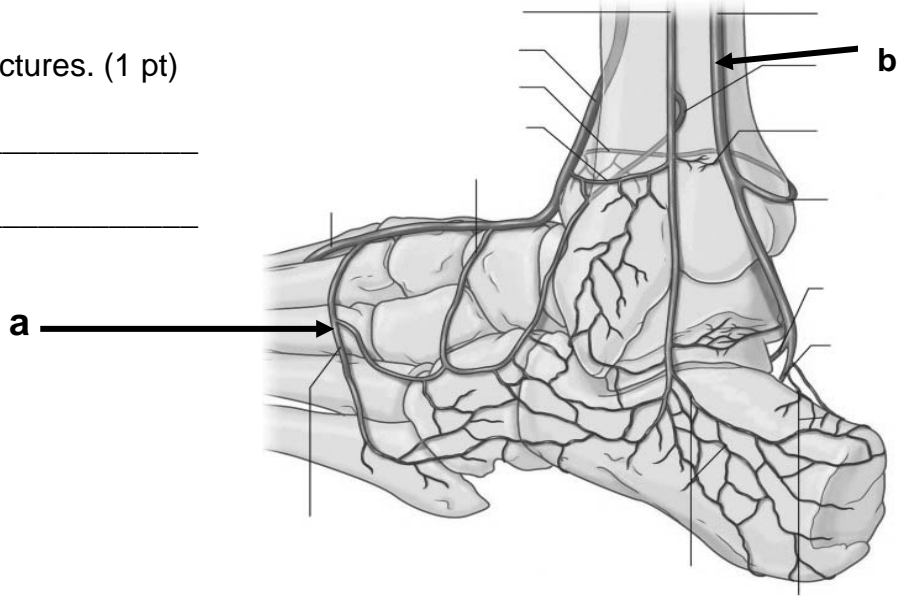
b. \_\_\_\_\_



5. Identify the structures. (1 pt)

a. \_\_\_\_\_

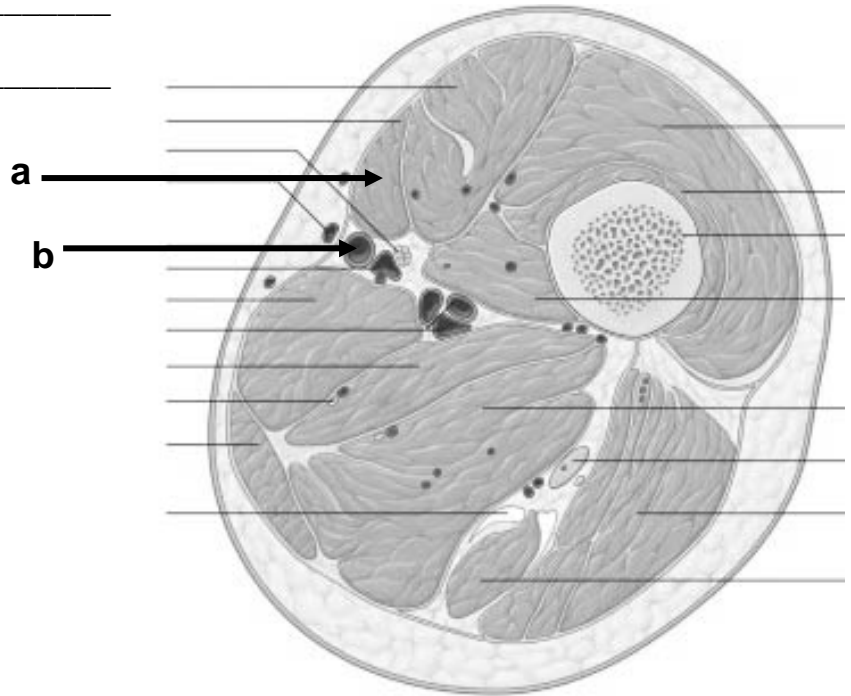
b. \_\_\_\_\_



6. Identify the structures (at level of femoral femoral triangle). (1 pt)

a. \_\_\_\_\_

b. \_\_\_\_\_



**Part II. Circle the correct answer. All, none, or some may apply. (34 pts)**

1. With respect to the nervous system:

- a. Spinal nerves T1-L3 contain a white ramus communicans that transmits a pre-ganglionic sympathetic nerve fiber.
- b. The visceral layer of serous pericardium has sensations of touch and temperature.
- c. The ventral horn contains somatic efferent nerves.
- d. The diaphragm is an example of skeletal muscle that is innervated by the sympathetic and parasympathetic nerves.
- e. The parasympathetic division of the autonomic nervous system originates at L4-S4.
- f. Somatic pain is more localized and precise in location than visceral pain.
- g. The sympathetic nerves vasodilate the coronary arteries.
- h. The greater splanchnic nerve consists of post-ganglionic contributions from T5-9.
- i. The sympathetic trunk lies lateral to the lesser splanchnic nerve.
- j. The superficial cardiac plexus is formed in part by the sympathetic and parasympathetic nerves and is located in the concavity of the tracheal bifurcation.
- k. Visceral efferent nerves have cell bodies in the ventral root ganglion.
- l. The parietal pleura is innervated by the autonomic nervous system.

2. In regard to the subinguinal/femoral region:

- a. The femoral sheath encloses the femoral canal.
- b. The lateral femoral circumflex artery arises from the profunda (deep) femoral artery and courses posterior to rectus femoris, sartorius, and adductor longus muscles.
- c. The obturator artery supplies blood to the adductor muscles, head of the femur, and the obturator externus and internus muscles.
- d. The descending branch of the lateral femoral circumflex artery can be found with the adductor magnus muscle.

- e. The femoral nerve is a branch of the sacral plexus.
  - f. The falciform margin of the saphenous opening is derived from tela subcutanea.
  - g. The adductor longus muscle forms in part the floor of the femoral triangle.
  - h. The deep femoral artery arises superior to the femoral sheath.
  - i. The saphenous nerve courses through the femoral triangle, adductor canal, and enters the popliteal fossa after exiting through the adductor hiatus.
  - j. Femoral hernias are more common in women, and herniated contents are enclosed in part by the femoral sheath.
  - k. The 1st perforating artery of the inferior gluteal artery contributes to the cruciate anastomosis.
  - l. The vascular lacunae lies medial to the muscular lacunae.
  - m. The neck of a femoral hernia lies superior and medial to the pubic tubercle.
  - n. The tela subcutanea condenses to form the investing fascia of the thigh.
3. In regard to foot, arches, and gait:
- a. The posterior lateral malleolar artery is a branch of the peroneal artery.
  - b. Digits 2-5 have an extensor digitorum longus.
  - c. The heads of the flexor hallucis longus contain sesamoid bones.
  - d. The 5th digit is abducted by the dorsal interosseous muscle.
  - e. The longitudinal arch is supported anteriorly on the heads of the metatarsal bones.
  - f. The lumbricals flex the metatarsal phalangeal joint but extend the interphalangeal joints.
  - g. The adductor hallucis muscle is innervated by the medial plantar nerve.
  - h. The medial segment of the longitudinal arch includes the talus, navicular, 3 cuneiforms, and 3 medial metatarsals.
  - i. The short plantar ligament extends from the calcaneus to the cuboid bone.
  - j. The line of gravity passes in front of the hip and behind the knee and ankle when standing erect.

- k. The extensor expansion is formed in part by the extensor digitorum longus and brevis, and the lumbricals.
  - l. The swing phase of locomotion involves dorsiflexion.
  - m. The extensor digitorum longus inserts on proximal, medial, and distal phalanges.
  - n. A right inferior gluteal nerve injury could lead to pelvic sag/Trendelenberg's gait.
4. In the thorax:
- a. The sternopericardial ligaments are located in the anterior mediastinum.
  - b. The arch of the aorta is located in the inferior mediastinum.
  - c. The inferior part of the parietal pleura in thorax extends to the 8th costochondral junction in the mid-clavicular line.
  - d. The cervical dome of the pleura projects above the clavicle.
  - e. The thoracic duct lies medial to the sympathetic trunk in the posterior mediastinum.
5. With respect to the gluteal region:
- a. The obturator externus tendon courses through the lesser sciatic foramen.
  - b. Intragluteal injections should avoid the upper and outer quadrant.
  - c. The ischial tuberosities and the greater trochanter are on the same horizontal plane.
  - d. The gluteus maximus rotates the thigh/hip joint medially.
  - e. The tensor fascia lata muscle is vascularized in part by the superior gluteal artery.
  - f. The superior gemellus muscle takes its origin from the ischial spine.
6. "This and that".
- a. Foreign objects are more likely to lodge in the right bronchus.
  - b. The rectus femoris, but not the vastus intermedius, flexes the hip and flexes the knee.
  - c. The superficial external pudendal artery courses through the saphenous opening.
  - d. Blood flows from the deep to the superficial veins in the leg.

- e. The sternal angle indicates the 1st rib
- f. The deep cardiac plexus is located on the anterior surface of the tracheal bifurcation.
- g. The popliteus muscle can rotate the leg laterally and rotate the femur medially.
- h. The posterior compartment of the thigh is vascularized by branches of the deep femoral artery and vein.
- i. The lesser splanchnic nerve contains preganglionic sympathetic fibers.
- j. The great and small saphenous vein are derived from the dorsal venous arch.
- k. The flexor retinaculum extends between the medial malleolus and the medial tubercle of the calcaneus.
- l. The soleus and gastrocnemius muscles arise from the femur.
- m. The foot is more stable in a dorsiflexed position than a plantar flexed position.
- n. The fibular (lateral) ligament is intrasynovial but extracapsular.
- o. The phrenic nerve lies in the endothoracic fascia between the fibrous coat of the pericardium and the fibrous layer of the parietal pleura.
- p. The anterior cardiac veins drain into the right atrium.
- q. The greater splanchnic nerve contributes fibers to the SA node of the heart.

**Part III. Indicate your understanding (characteristics, importance, function, and/or contents) of the following. Answer in the space provided (including back of page). (24 pts)**

1. The function of the thorax is dependent on blood supply. **Discuss the collateral circulation (arteries/veins, relationships to surrounding structures, parent arteries/veins) of the thoracic wall.** (8 pts)



EXAM NUMBER \_\_\_\_\_

2. Acute pericarditis is an inflammatory process involving the pericardium that results in a clinical syndrome with the triad of chest pain, pericardial friction rub, and changes in the electrocardiogram (ECG). **Discuss the structure of the pericardium/pericardial sac, including innervation, vascularization, lymphatics, and means of stabilization.** (8 pts)

EXAM NUMBER \_\_\_\_\_

3. Strain of the hamstring muscles is common in runners, and alteration of hamstrings is important in disease such as spastic cerebral palsy. **Discuss the anatomy of the hamstring muscles including criteria for inclusion, innervation, vascularization, and function.** (8 pts).

EXAM NUMBER \_\_\_\_\_

**Part IV. Answer in the space provided (including the back of the page for each question). (36 pts)**

1. A 25 year old male is the unrestrained driver of a motor vehicle involved in a high speed head on collision. His feet are impacted into the floor. X-rays of the right ankle taken in the Emergency Department reveal a displaced fracture of the calcaneus through the attachments of the calcanofibular and tibiocalcaneal ligaments. As a 2nd year resident, you are asked to:  
**Review structures related to the medial region of the ankle. Include bones, muscles, fascia, retinacula, innervation, articulation and movements, medial longitudinal arch, as well their anatomic relationship. Also discuss the effects on foot movement(s) and gait.**  
(12 pts)

EXAM NUMBER \_\_\_\_\_

EXAM NUMBER \_\_\_\_\_



2. A 66 year old male is admitted to the general medicine ward service with respiratory failure that requires mechanical ventilation. In discussing the case, it is unclear if it is due to a disease process affecting the muscles of respiration or the nerves that innervate the various mechanisms involved in breathing. In order to understand which structure may be the cause of his respiratory failure your attending physician asks you to: **Discuss the mechanics of breathing, focusing on explaining the basic movements (including joints) of the thoracic cage and expansion of the lung in respiration.** (12 pts)

EXAM NUMBER \_\_\_\_\_

**EXAM NUMBER** \_\_\_\_\_

3. An 18 year old football player is tackled during a football game. He falls to the ground holding his left knee. When reviewing the video replay of the tackle, it is noted that he was struck on the posterior lateral aspect of the knee. On exam, he has "a positive anterior drawer sign" (forward sliding of tibia) and tenderness and laxity (relaxation/looseness) of the medial joint space of the knee when valgus (bending/twisting) stress is placed on it. **Discuss the anatomy of the knee joint. Include bones, cartilage, ligaments, muscles, bursa, vascular supply, innervation, stabilization, center of gravity, and locking/unlocking of the knee joint.** (12 pts)

EXAM NUMBER \_\_\_\_\_

EXAM NUMBER \_\_\_\_\_