

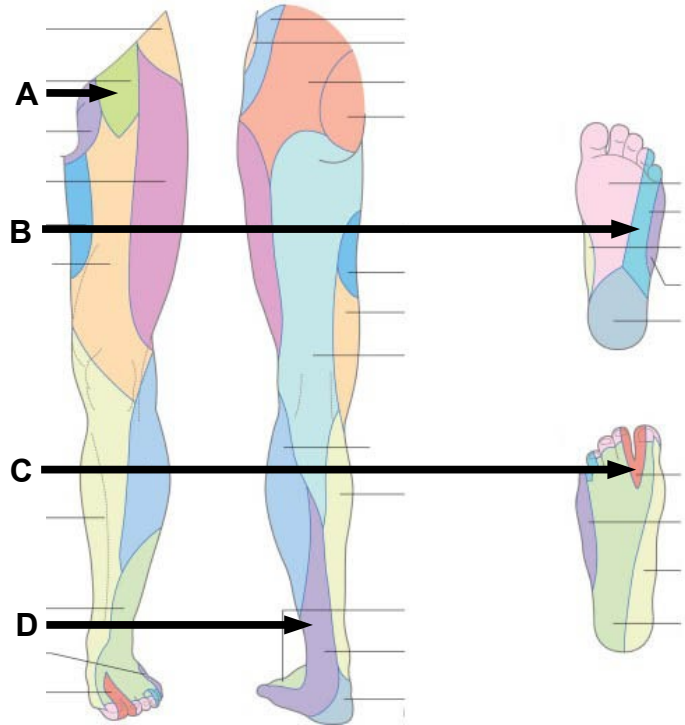
Graduate Anatomy EXAMINATION 1

September 17, 2021

PART I. Answer in the space provided. (12 pts)

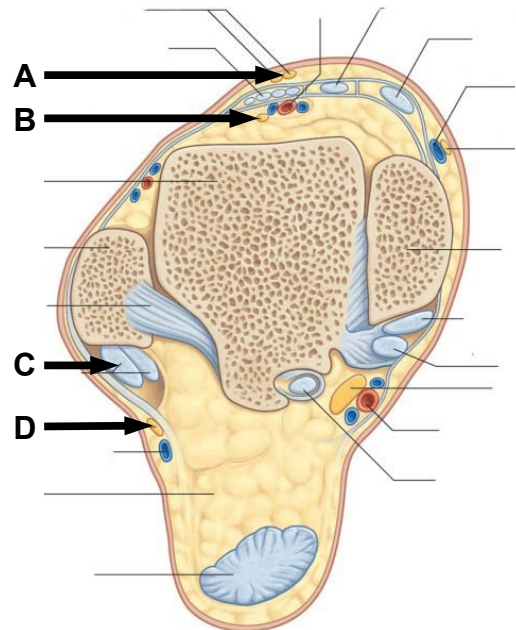
1. Identify the Nerve Distributions. (2 pts)

- A. _____
- B. _____
- C. _____
- D. _____



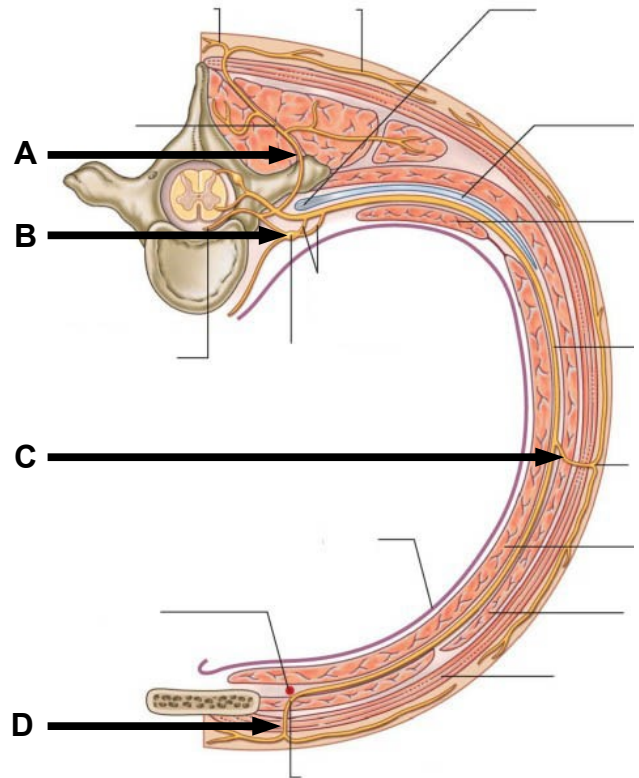
2. Identify the structures. (2 pts)

- A. _____
- B. _____
- C. _____
- D. _____



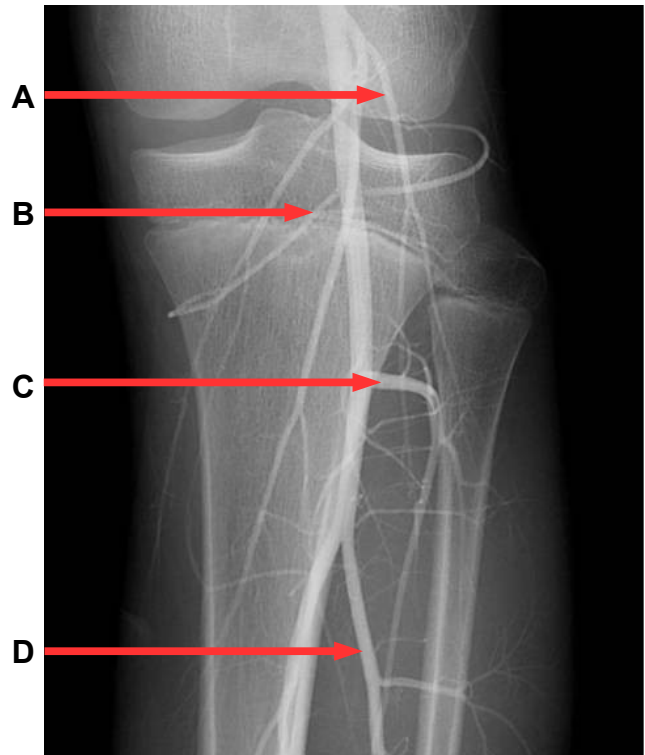
3. Identify the structures. (2 pts)

- A. _____
- B. _____
- C. _____
- D. _____



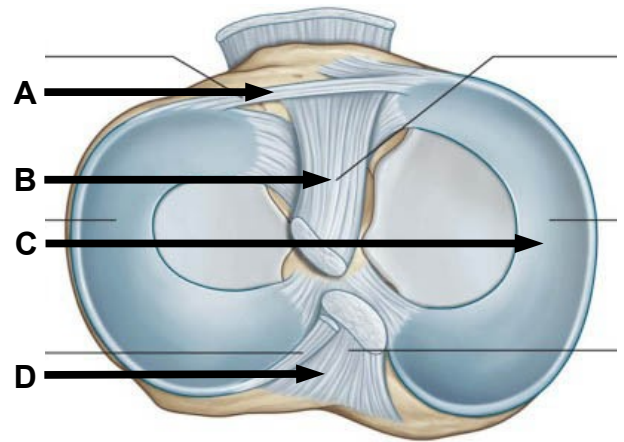
4. Identify the structures. (2 pts)

- A. _____
- B. _____
- C. _____
- D. _____



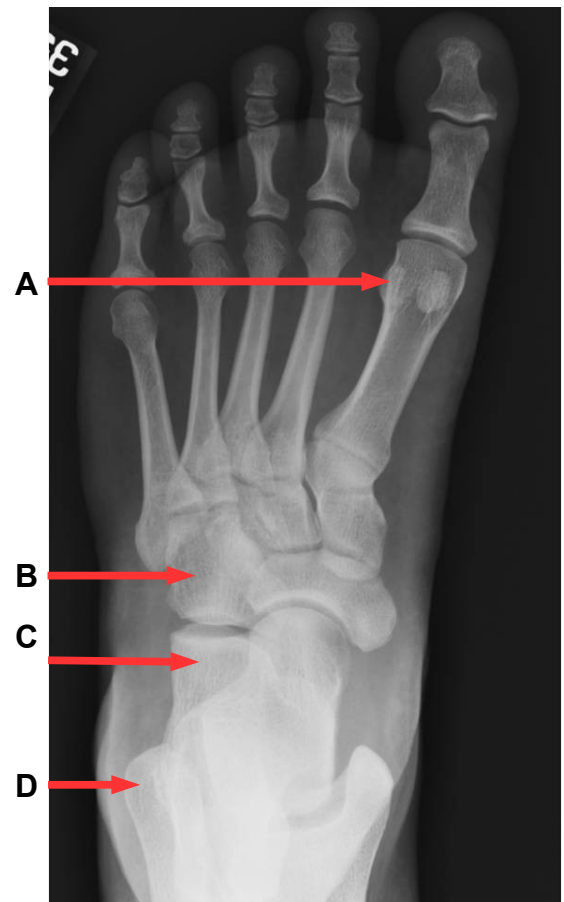
5. Identify the structures. (2 pts)

- A. _____
- B. _____
- C. _____
- D. _____



6. Identify the structures. (2 pts)

- A. _____
- B. _____
- C. _____
- D. _____



Part II. Circle the correct answer. All, none, or some may apply. (10 pts)

1. With regard to the thigh:

- a. The femoral artery enters the popliteal fossa along with the saphenous nerve.
- b. The falciform edge of the saphenous hiatus is anterior to the femoral vein.
- c. The suprapatellar bursa communicates with the synovial joint cavity of the knee.
- d. The lesser saphenous vein enters the popliteal fossa by passing through the investing fascia.
- e. The ascending branch of the second perforating artery contributes to the cruciate anastomosis.
- f. The gluteus maximus muscle inserts onto the iliotibial tract and gluteal tuberosity.

3. With regard to the hip joint:

- a. The artery of the ligament of the head of the femur is a branch of the medial circumflex femoral artery.
- b. The transverse acetabular ligament and acetabular notch form an osseofibrous foramen that transmits the artery of the head of the femur into the acetabular fossa.
- c. The straight head of rectus femoris and the pubofemoral ligament attach at the anterior inferior spine.
- d. The acetabular labrum forms a continuous ring that bridges the acetabular notch.

4. With regard to the knee joint:

- a. The middle genicular artery passes through the oblique popliteal ligament.
- b. The coronary ligaments attach the medial and lateral menisci to the femoral condyles.
- c. The anterior cruciate ligament attaches to the medial side of the lateral femoral condyle and to the anterior intercondylar eminence of the tibia.
- d. The popliteus muscle laterally rotates the hip to unlock the extended knee.
- e. The cruciate ligaments of the knee are extrasynovial and intracapsular.

5. With regard to the thorax:

- a. The right posterior intercostal arteries pass deep to the azygos vein and deep to the thoracic sympathetic trunk.
- b. The inferior border of the superior mediastinum is defined by a line from the jugular notch to the T4 vertebra.
- c. The venous mesocardium defines the boundaries of the oblique sinus.
- d. The arch of the azygos receives drainage from the right supreme intercostal vein.
- e. Thoracic splanchnic nerves branch from the anterior side of parasympathetic trunk ganglia.

Part III. Indicate your understanding of the following. Answer in the space provided. (30 pts)

- 1. The heart myocardium receives arterial blood supply during diastole. Discuss the anatomy and function of the aortic semilunar valve. Discuss blood flow within the coronary arteries during the cardiac cycle. (6 pts)**

2. The leaflets of the tricuspid valve are closed by ventricular hemodynamics and held closed by anatomical structures. **Discuss the anatomy and function of Tricuspid valve. (6 pts)**

3. Entrapment of the lateral femoral cutaneous nerve causes paraesthesia of the lateral thigh known as meralgia paresthetica. **Discuss the anatomy of the lateral femoral cutaneous nerve. Account for clinical significance of paraesthesia along a peripheral nerve distribution compared to paraesthesia along a dermatome distribution. (6 pts)**

4. Stabilizing the pelvis during the gait cycle requires proper function of the hip abductors. **Discuss the anatomy of the superior gluteal nerve. Include foramina, relationships, and innervated muscles. Account for functional deficits following injury to the superior gluteal nerve within the context of Trendelenburg gait. (6 pts)**

5. Movement of the thoracic wall is required for respiration. **Discuss the anatomical basis for expansion along the anterior/posterior axis of the thorax known as pump handle movement. (6 pts)**

Part IV. Essay. (48 pts)

1. Twelve percent of the women in the United States develop metastatic breast cancer. **Discuss the anatomy of the right female breast. Include fascia, vasculature, innervation, relationships, glandular tissues, lymphatic drainages, and support. Account for fascial barriers that may impede the contiguous spread of cancer into the thoracic cavity and lung. Account for metastatic spread to the left breast and to superficial inguinal lymph nodes. Include an instance of clinical significance. (12 pts)**

EXAM NUMBER _____

EXAM NUMBER _____

2. A 46-year-old carpenter stepped on a nail that penetrated the medial sole of the foot. **Discuss the skin, fascia, muscles, tendons, nerves, vasculature, ligaments, bones, and lymphatic drainage at risk by a penetrating injury that pierces the spring ligament. Discuss the support of the medial longitudinal arch. Include an instance of clinical significance. (12 pts)**

EXAM NUMBER _____

EXAM NUMBER _____

3. Enlarged lymph nodes secondary to infection of the dorsal lateral foot may compress structures within the popliteal fossa. **Review the boundaries, contents, and relationships of the popliteal fossa. Include skin, fascia, ligaments, bones synovial diverticula, vasculature, lymphatic drainages, and muscles. What functional deficits may result from compression of structures within the popliteal fossa? Include an instance of clinical significance. (12 pts)**

EXAM NUMBER _____

EXAM NUMBER _____

4. Hip pain may be caused by trochanteric bursitis or osteoarthritis. **Review the anatomy and stability of the hip joint. Account for bones, articular surfaces, ligaments, innervation, vasculature, lymphatic drainage, movement, and limits of movement. Include an instance of clinical significance. (12 pts)**

EXAM NUMBER _____

EXAM NUMBER _____