

Core Anatomy
EXAMINATION 1

August 16, 2013

PART I. Answer in the space provided. (12 pts)

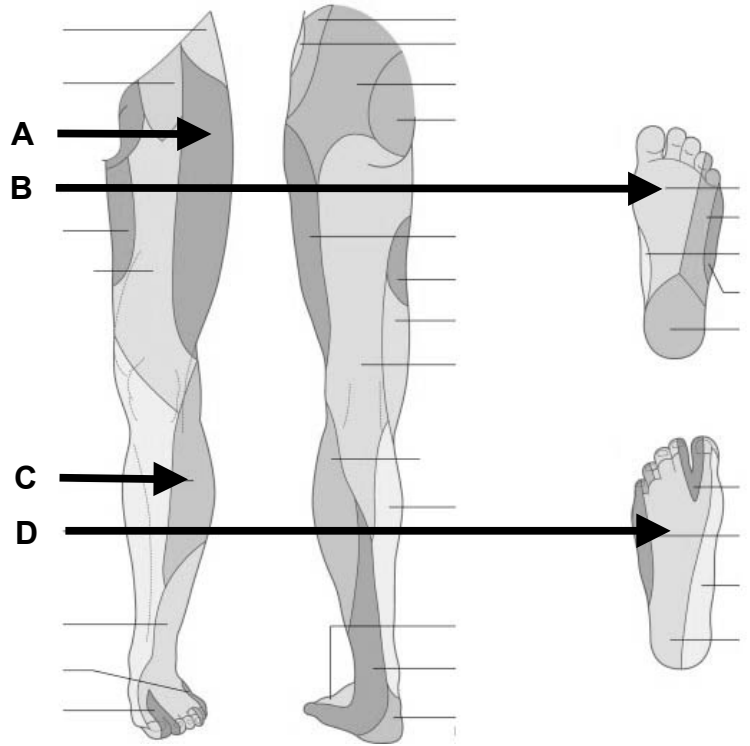
1. Identify the distributions. (2 pts)

A. Lat. Fem. Cut. Nerve

B. Medial Plantar Nerve

C. Lateral Sural Cut. Nerve

D. Superficial Peroneal Nerve



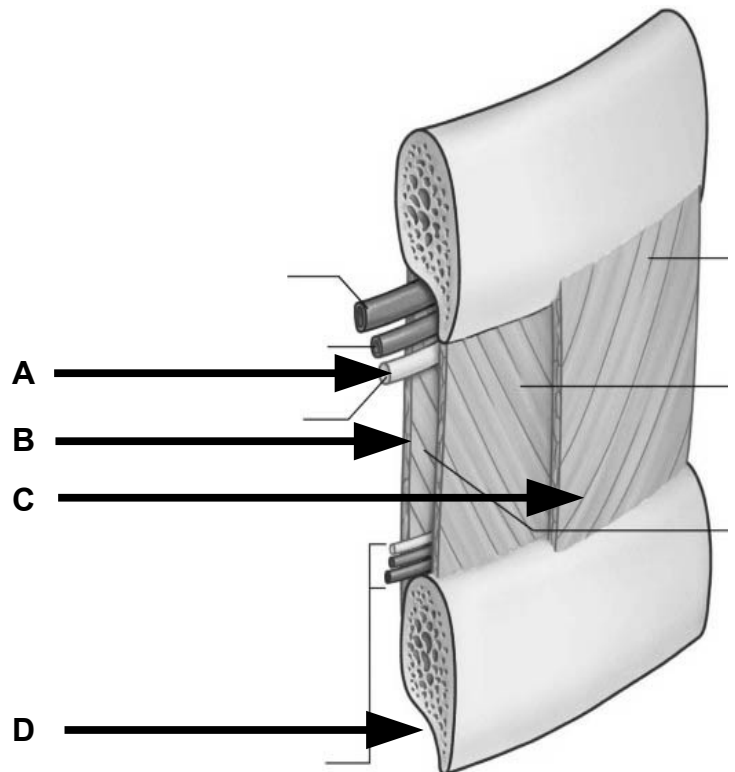
2. Identify the structures. (2 pts)

A. Intercostal Nerve

B. Innermost Intercostal Muscle

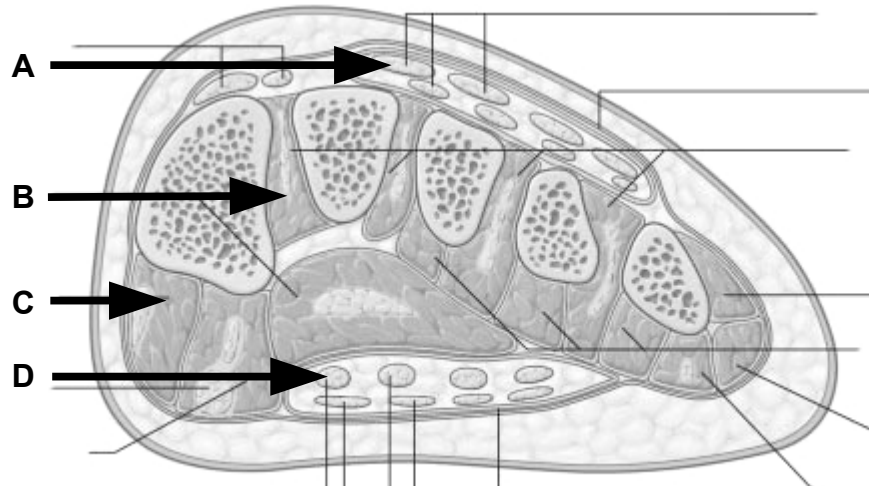
C. External Intercostal Muscle

D. Costal Groove



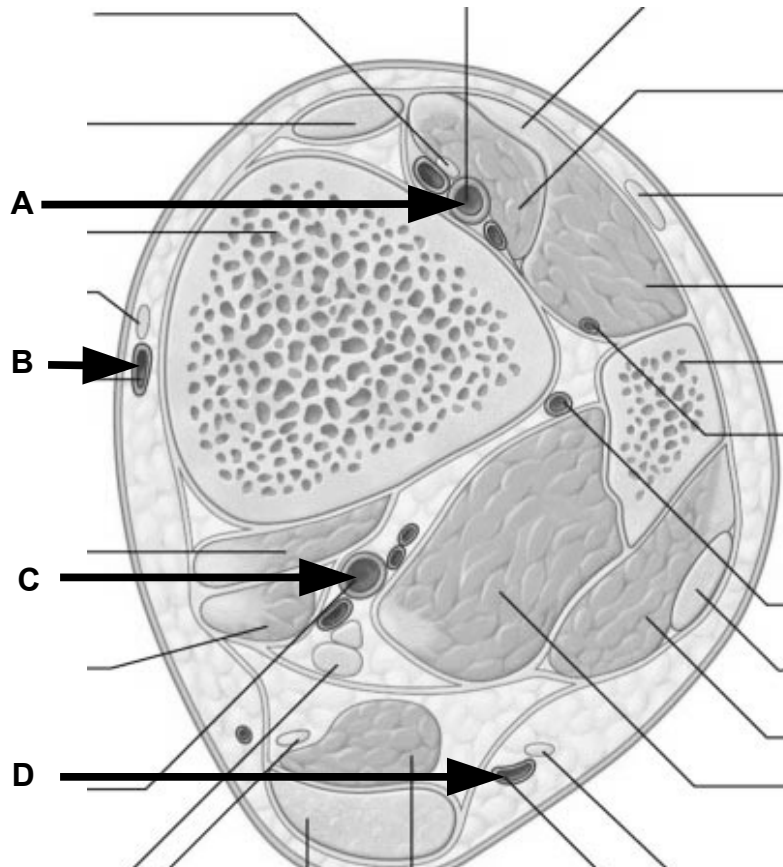
3. Identify the structures. (2 pts)

- A. Extensor Digitorum Longus M.
- B. First Dorsal Interosseus M.
- C. Abductor Hallucis M.
- D. Flexor Digitorum Longus M.



4. Identify the vessels. (2 pts)

- A. Anterior Tibial Artery
- B. Great Saphenous Vein
- C. Posterior Tibial Artery
- D. Lesser Saphenous Vein



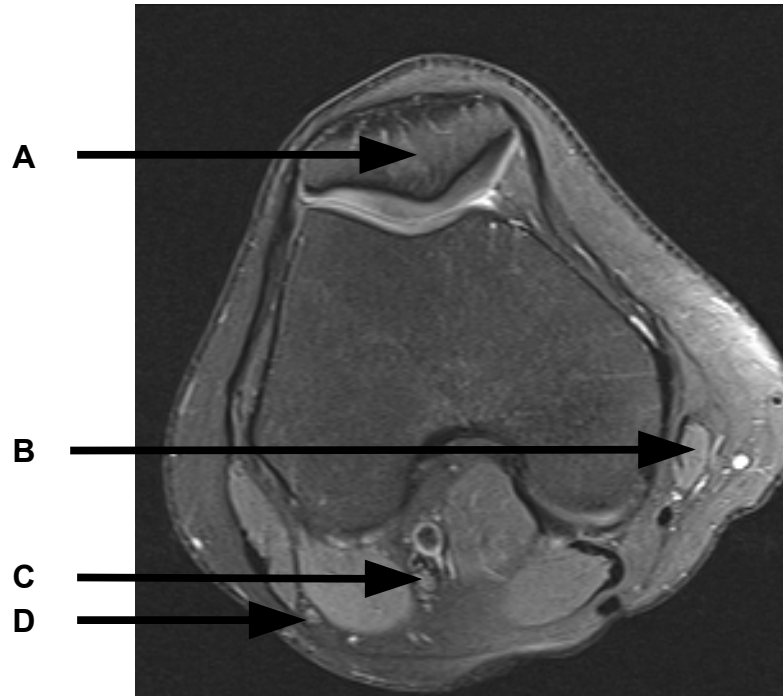
5. Identify the structures. (2 pts)

A. Patella

B. Sartorius Muscle

C. Tibial Nerve

D. Common Peroneal Nerve



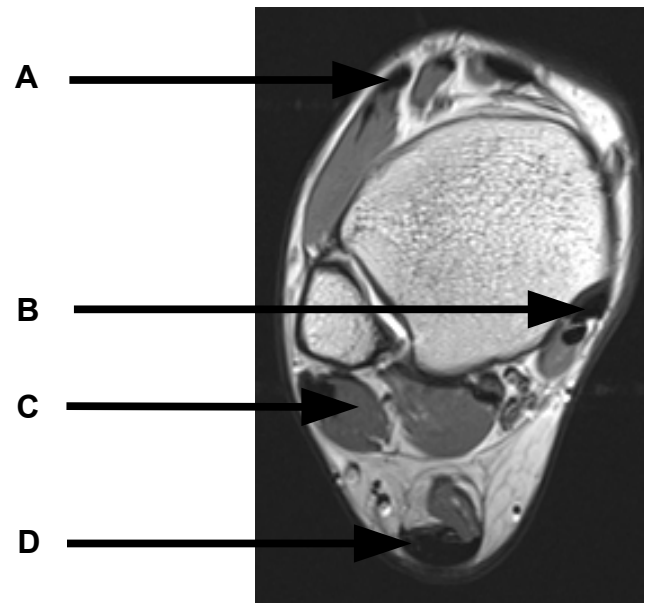
6. Identify the structures. (2 pts)

A. Extensor Digitorum M.

B. Tibialis Posterior M.

C. Peroneus Brevis M.

D. Tendocalcaneus



Part II. Circle the correct answer. All, none, or some may apply. (10 pts)

1. With regard to the gluteal region:
 - a. The obturator externus inserts at the trochanteric fossa and medially rotates the thigh.
 - b. In addition to the iliotibial tract, the gluteus maximus inserts onto the gluteal tuberosity.**
 - c. The pudendal nerve passes through the greater sciatic foramen to enter the gluteal region from the pelvis.
2. With regard to the thigh:
 - a. Within the adductor canal the femoral artery lies deep to the femoral vein.
 - b. The short head of the biceps femoris flexes the knee regardless of whether the hip is extended.**
 - c. The tendons of the sartorius, gracilis, and semitendinosus muscles contribute to the formation of the oblique popliteal ligament.
3. With regard to the leg:
 - a. The interosseous membrane provides a posterior boundary to the anterior compartment of the leg.**
 - b. Anterior compartment syndrome may compress the superficial peroneal nerve.
 - c. The lateral compartment of the leg is supplied by branches of the peroneal artery and vein.**
 - d. The sural arteries arise from the popliteal artery.**
4. With regard to the foot:
 - a. The tendons of extensor digitorum brevis converge onto the tendons of extensor digitorum longus from the medial side.
 - b. The ankle is more stable in a dorsiflexed (extended) position than in a plantar flexed (flexed) position.**
5. With regard to the joints of the lower extremity:
 - a. The arcuate ligament crosses the posterior surface of the popliteus muscle.**
 - b. The iliofemoral ligament resists extension and the pubofemoral ligament resists abduction.**

6. With regard to the thoracic wall and respiration:

- a. **During inspiration the upper ribs increase the vertical diameter of the thoracic cavity.**
- b. The costotransverse joints of the upper ribs are more planar than the lower ribs.

7. With regard to the mediastinum:

- a. **The superior border of the superior mediastinum is defined by a line from the jugular notch to the T1 vertebra.**
- b. **The phrenic nerve passes anterior to the hilum of the lung.**
- c. **The coronary arteries receive blood from the aortic sinuses during diastole.**
- d. **The chordae tendineae from a single papillary muscle extend to more than one cusp**

Part III. Indicate your understanding of the following. Answer in the space provided. (30 pts)

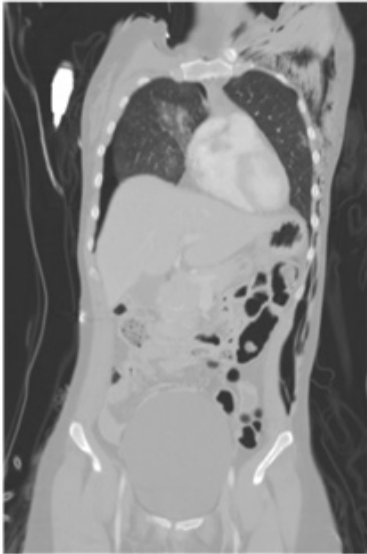


Figure A

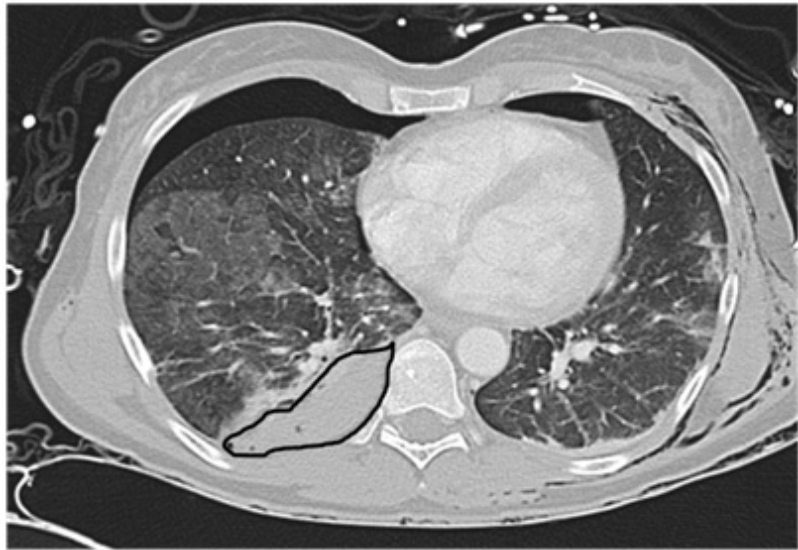

Figure B

1. A 45 year old male presents to the emergency department 30 minutes after sustaining multiple stab wounds to the chest in a bar fight. The entrance wounds are along the right, anterior axillary Line. The patient is complaining of chest pain, is tachypneic (high respiratory rate), and hypotensive (low blood pressure). A CT scan is shown with the resulting findings: Figure A is a coronal view and Figure B is an axial View.

1. Based on this case presentation and the radiological images, **please describe the layers, from superficial to deep, that the knife traversed which resulted in this pneumothorax** (Figure A & B White Arrow). (6 pts)

In addition to the pneumothorax , the axial CT scan reveals a pleural effusion as well (Figure B, Black Arrow & Black Outline). In order to evaluate the fluid content in this area you (the physician) perform a thoracentesis by a posterior approach.

2. **What anatomical location and landmarks help you denote and identify the “safest” approach to this procedure and explain why you are choosing this particular anatomy to guide you in this diagnostic procedure? When discussing the potential complications that occur during a thoracentesis, which structures are at greatest risk for injury with this procedure?** (6 pts)

EXAM NUMBER _____

EXAM NUMBER _____

2. An intragluteal injection into the upper medial quadrant may damage the superior gluteal nerve and cause Trendelenburg gait. **Discuss the anatomy and relationships of the superior gluteal nerve and the consequences of damage to this nerve. (6 pts)**

3. The sustentaculum tali is a notable landmark of the ankle region. **Discuss the relationships of the sustentaculum tali and the consequences of injury to this area. (6 pts)**

4. The coronary arteries perfuse (supply blood) the heart during diastole (relaxation of the myocardium). **Discuss the anatomy of the aortic valve (semilunar). Provide an account for coronary blood flow during diastole. (6 pts)**

Part IV. Clinical Correlations. (48 pts)

Provide comments about your evaluation of each choice.

1. A 66 year old male presents to the emergency department 45 minutes after developing severe substernal chest pain. He also complains of nausea and shortness of breath. The pain is 10/10 and radiates to his left shoulder. The patient's EKG shows signs of an acute myocardial infarction but no heart block is noted. He is taken emergently to cardiac angiography and findings are consistent with a 90% occlusion of a single coronary. He has a left side dominant coronary anatomy. The decision is made to open the artery and place a stent. When the balloon is inflated to perform the angioplasty, it is noted on fluoroscopy that the patient's posterior 1/3 of the interventricular septum becomes hypokinetic. The remainder of the heart muscle contracts normally. His heart rate and blood pressure continue to be within normal limits also. **Which of the following arteries is most likely the site of occlusion in this patient? (12 pts)**
 - a) right coronary
 - b) left main coronary
 - c) distal left anterior descending (distal anterior interventricular)
 - d) distal circumflex supplying posterior interventricular artery
 - e) nodal

EXAM NUMBER _____

2. A 32 year old professional female soccer player falls to the turf, clutching her knee after a collision with two players while attempting a shot on goal. She states that upon impact with the ball she felt resistance and immediate knee pain. Examination on the field is performed. There is no obvious effusion, erythema or warmth. Varus and valgus stress to the joint does not reproduce her pain or display joint instability. When lying supine with her foot flat on the ground and the knee at a 45 degree angle, an anterior and posterior drawer test is performed. During these maneuvers, there is excessive posterior translation of the femur on the tibial plateau. In addition, with the lower extremity flexed at 90 degrees, the medial knee stabilized at 90 degrees, and internal rotation of the foot is performed while the knee is fully extended (McMurray's test) the knee notes a "popping" sound and exacerbation of her pain. **Given these findings, which of the following structures is most likely injured in this patient? (12 pts)**
- a) Anterior cruciate ligament; medial collateral ligament
 - b) Anterior cruciate ligament; lateral collateral ligament
 - c) ***Anterior cruciate ligament; lateral meniscus***
 - d) Posterior cruciate ligament; medial collateral ligament
 - e) Posterior cruciate ligament; lateral collateral ligament

EXAM NUMBER _____

3. A 25 year old professional football player injures his right knee while being tackled by several defensive players. He has difficulty bearing weight and is carried off the field. You examine him on the sidelines by putting his knee through several maneuvers. When placing valgus stress on the right knee you note that the joint space on the inside of his knee opens. Varus stress does not cause a similar finding on the joint spaces. When performing the anterior and posterior drawer sign, you note that there is increased translation (movement) of the tibia, backward, on the femur. **Which one of the following structures is most likely torn in this patient? (12 pts)**
- a. Anterior Cruciate ligament and medial meniscus
 - b. Anterior cruciate ligament and lateral meniscus
 - c. Medial collateral ligament and medial meniscus
 - d. Lateral collateral ligament and lateral meniscus
 - e. Posterior cruciate ligament and medial collateral ligament

EXAM NUMBER _____

4. An 18 year old male sustains a through and through gunshot wound to his left thigh. In the emergency department, he is complaining of severe left thigh pain and swelling. On exam, his temperature is 37.5 C, pulse is 115 beats per minute and his blood pressure is 110/58. He describes his pain as 10/10. His left lower extremity, above the knee, shows an entrance wound in the body of the vastus medialis. The thigh is enlarged, tense, warm and dark red in color. There is concern for an arterial injury within the adductor canal. The pressure within the thigh is measured and it is determined that compartment syndrome is impending. **If repair of the artery is delayed, which of the following is most likely to be experienced by the patient as a result of increased pressure on the structures within this canal? (12 pts)**
- a) Thrombus within the great saphenous vein
 - b) Reduced arterial blood flow to the muscles in the posterior compartment of the thigh
 - c) ***Numbness on the medial side of the leg and foot***
 - d) Loss of flexion of the knee joint
 - e) Chronic lymphedema

EXAM NUMBER _____